

UDC 591.48:598.115.31

## THE TERMINAL AND VOMERONASAL NERVES OF MONTPELLIER SNAKE, *MALPOLON MONSPESSULANA* (COLUBRIDAE, OPHIDIA, SQUAMATA)

A. R. Omar<sup>1</sup>, A. I. Dakrory<sup>1,2</sup>

<sup>1</sup>Department of Zoology, Faculty of Science, Cairo University

<sup>2</sup>Department of Biology, Faculty of Science, Taif University

<sup>1</sup>E-mail: amel@sci.cu.edu.eg

**The Terminal and Vomeronasal Nerves of Montpellier Snake, *Malpolon monspessulana* (Colubridae, Ophidia, Squamata).** Omar, A. R., Dakrory, A. I. — The montpellier snake, *Malpolon monspessulana*, used in the current work in order to study the nervi terminalis and vomeronasalis. The vomeronasal organ or Jacobson's organ is a part of the olfactory apparatus. This organ is innervated by the terminal and vomeronasal nerves. These nerves emerge from the sensory epithelium of Jacobson's organ simultaneously. The bundles of the terminal and vomeronasal nerves traverse together the cavity of the nasal capsule in their way to the brain. These nerves bear scattered ganglionic cells which represent the ganglion terminale. They leave the capsule through the foramen olfactorium advehens. The terminal and vomeronasal nerves are connected with the olfactory nerve and enter the olfactory formation of the forebrain.

**Key words:** terminal nerve, vomeronasal nerve, Jacobson's organ, *Malpolon monspessulana*.

### Introduction

Colubrid snakes form one of the largest families of the suborder Ophidia of the order Squamata. Some studies were carried out on the Montpellier snake, *Malpolon monspessulana*, under investigation such as the study of the chondrocranium (El Toubi et al., 1973) and the developmental study of the vomeronasal organ of Jacobson (Salah EL-Din, Dakrory, 2015). However, any data about the cranial nerves of this snake were not obtained (Dakrory, Omar, 2014). Concerning the cranial nerves in reptiles, in general, many studies were reported in Ophidia and Lacertilia such as Mostafa (1991) on Ophidia, Dakrory (1994) on the amphisbaenian *Diplometoponzarudnyi*, Abdel-Kader (2006) on the cat snake *Telescopus dhara*, Abdel-Kader et al. (2007) on *Mabuya quinquetaeniata*, Dakrory (2011) on *Uromastix aegyptius* and Omar (2013) on *Coluber rogersi*.

In this study, it is to the point to study the terminal and vomeronasal nerves in the snake *Malpolon monspessulana* that innervate the vomeronasal organ. This may help in understanding the phylogeny, taxonomy and behavior of this primitive ophidian family.

### Material and methods

The species used in this study is the Montpellier Snake, *Malpolon monspessulana*, of the Family: Colubridae. According to Bernhard (1971) it distributed from North Africa to south western Asia. In Egypt, the Montpellier inhabits western Mediterranean coastal desert, Nile Delta, lower valley and Siwa oasis. It found in the semi-desert, sandy areas of northern Delta, around vegetated salt marshes and in cultivated land. It feeds on small mammals, lizards, frogs and birds. Variations in its color include reddish individuals. Three specimens of the fully formed embryo are collected from Baltim, north coast of Egypt. The heads of the three specimens were cut and fixed in Bouin's fixative for 24 hours. The heads were treated with EDTA solution for decalcification. Taken time for decalcification process 40 days, during which the EDTA solution was changed every 4 days. This was followed by washing the embryos several times with 70 % ethyl alcohol. After that, the heads are treated to ascending series of ethyl alcohol and then cleared with xylene. Thereafter, the heads were embedded in paraffin wax. Then serial transverse sections were obtained at thickness 10 µm using the microtome. The sections were stained in haematoxylin and then counter stained with eosin. Some transverse sections were photographed to show the relation between the terminal and vomeronasal nerves to the different parts of the head.

## Results

In *Malpolon monspessulana*, the fibres of the nervus terminalis originate from the sensory epithelium of the vomeronasal organ of Jacobson, in association with those of the vomeronasal nerve (fig. 1, 2, N.0). It is considered as a small ganglionated sensory nerve appears just anterior to the other cranial nerves. Embryologically, the vomeronasal organ begotten from the medial side of the olfactory chamber during its early development and then it completely separates from the latter chamber to dwell ventral to it (fig. 1, JO). It is considered as a small ganglionated sensory nerve appears just anterior to the other cranial nerves.

The nerve fibres arise from the dorsal, medial and the lateral side of the biggest part of the anterior end of Jacobson's organ and congregate into two branches, dorsal to the latter organ (fig. 1, N.0). These branches receive many terminal fibres which issue from the dorsomedial, dorsal and the dorsolateral sides of the anterior third of the same organ. The two branches run posteriorly dorsal to the bulging sensory epithelium that lines the Jacobson's organ and ventral to the septomaxillary bone. As they extend backwards, new fine branches are gradually collected and extend posterodorsally to join the two main branches. Finally, these two branches are fused together forming a stout bundle.

From the dorsomedial, dorsal and dorsolateral sides of Jacobson's organ arise many nerve fibres that extend dorsally passing ventral to the first main bundle, dorsal to the latter organ, lateral to the nasal septum and medial to the olfactory chamber. These fibres were collected together into one bundle (fig. 3, N.0). The two bundles extend posterodorsally and enter the olfactory region passing ventral to the olfactory nerve bundles, medial to the olfactory chamber, lateral to the nasal septum and dorsal to the vomeronasal organ (fig. 4, N.0).

From the middle part of Jacobson's organ many fibres arise from its dorsal, lateral and medial sides. These fibres congregated into one bundle, which runs ventral to the first two ones, lateral to the nasal septum and medial to the posterior part of the olfactory chamber (fig. 4, N.0). More backwards, the three bundles joined into one large bundle.

Two bundles originate from the posterior portion of the vomeronasal organ and extending dorsally to be close to the first one (fig. 5, N.0). From the most posterior part of Jacobson's organ, there is a branch extend to fuse with the terminal nerve in a position dorsal to the latter organ, ventral to the olfactory nerve, lateral to the nasal septum and medial to the olfactory capsule (fig. 6, N.0).

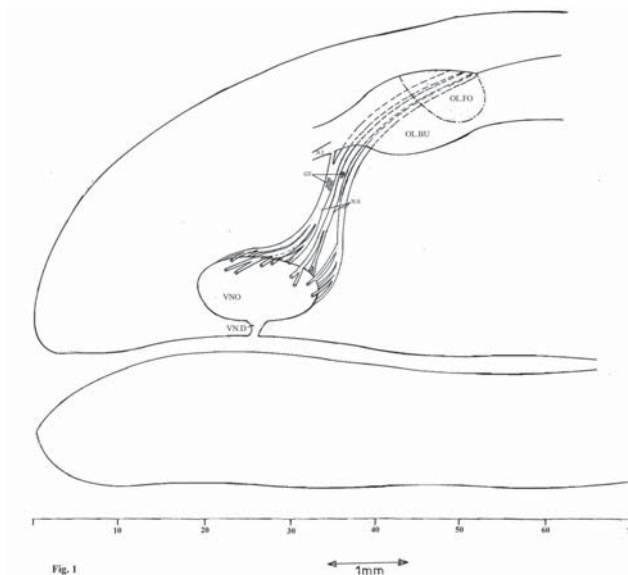


Fig. 1. Graphic reconstruction in a lateral view showing the contour of the vomeronasal organ (VNO), the vomeronasal duct (VND), the terminal and vomeronasal nerves (N.0) and the nervus olfactorius (N.I).

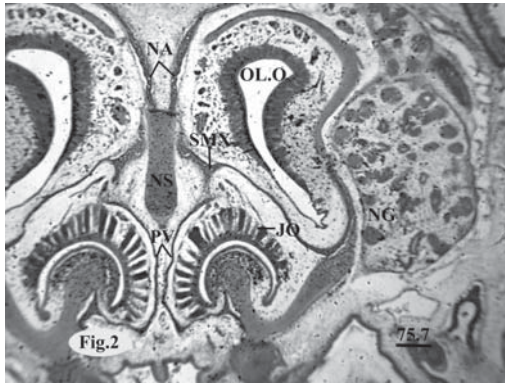


Fig. 2. Showing the origin of the nervus terminalis from the Jacobson's organ (JO), nasal bone (NA), nasal septum (NS), septomaxilla (SMX), prevomer (PV) and the olfactory organ (OLO).

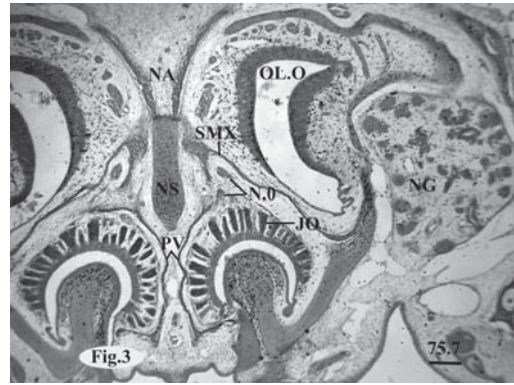


Fig. 3. Showing the first two bundles of the nervus terminalis.

Slightly backwards and dorsally within the nasal capsule, just before its entering to the cranial cavity, the terminal nerve carries two groups of scattered ganglionic cells. These groups represent the ganglion terminale (fig. 7, GT).

Posterior to the ganglion terminale, the bundles of the terminal and vomeronasal nerves leave the nasal cavity through a foramen olfactorium advehens (fig. 6, FOA). This one is in the form of a wide incisure rather than a complete foramen. Within this foramen, the olfactory nerve connects with the terminal and vomeronasal nerves (fig. 6, N.0, N.I). These nerves enter the cranial cavity by penetrating the membranous cranial wall as separate bundles. Intracranially, the bundles constituting the terminal and vomeronasal nerves pass ventromedial to those of the olfactory nerve (fig. 1, 8, N.0) for a short distance. Finally, the terminal and vomeronasal nerves enter the olfactory formation from its ventromedial side as separate bundles.

**Discussion**

In the Montpellier snake, *Malpolon monspessulana*, there are nerve fibres arising from the sensory epithelium of Jacobson's organ which are the terminal nerve. This nerve was first reported by Pinkus (1894) in the dipnoan *Protopterus annectens*. Thereafter, it was identified nearly in all vertebrate classes except cyclostomes and birds, as has been reported by Watanabe and Yasuda (1968), Romer and Parson (1985), Soliman et al. (1986), Dakrory (1994, 2005), El-Ghareeb et al. (2004), Shamakh (2009), Dakrory and Mahgoub

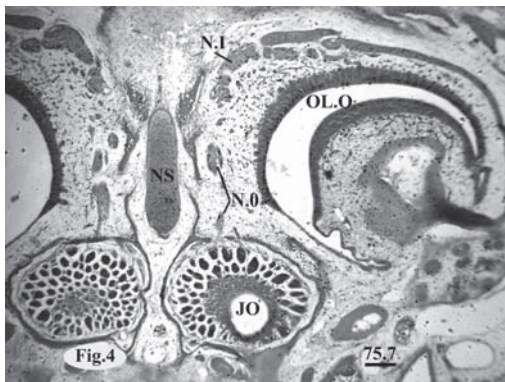


Fig. 4. Showing the origin of the fibres of the nervus terminalis from the middle part of Jacobson's organ.

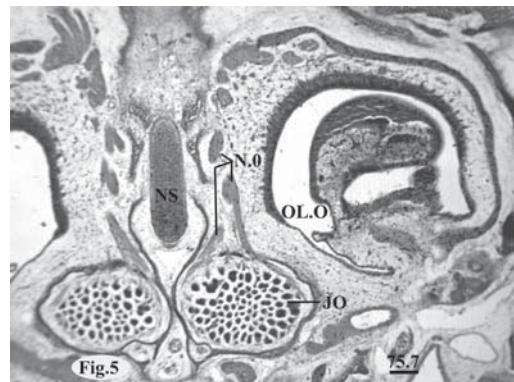


Fig. 5. Emergence of two bundles from the posterior part of the vomeronasal organ.



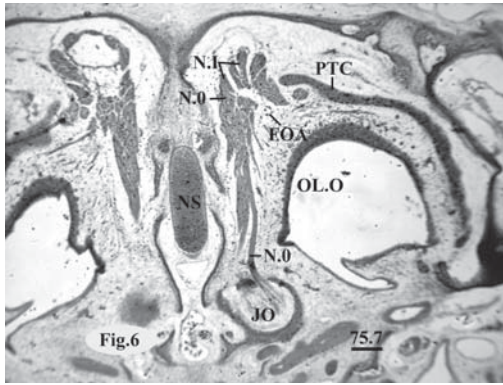


Fig. 6. Showing the position of the foramen olfactorium advehens (FOA) and the fusion between the nervi terminalis and olfactorius (N.I), parietotectal cartilage (PTC).




Fig. 7. Showing the ganglion terminale (GT), 12.5µm.

(2009), Alfitour (2010), Madboly (2011) and Dakrory et al. (2011). On the other hand, Von Bartheld et al. (1987) and Northcutt and Puzdrowski (1988) stated that a terminal nerve is found in lampreys, following the application of horseradish peroxidase to the olfactory mucous.

Kent (1978) suggested that this nerve is possibly a ganglionated remnant of an anterior branchial nerve which primitively innervated the mouth region.

Regarding the structural components of the terminal nerve, it was stated that this nerve contains elements of a sympathetic nature. According to De Beer (1924) the terminal nerve carries somatic sensory fibres in addition to some sympathetic ones. However, Jollie (1968) mentioned that this nerve is presumed to be a sensory nerve (general cutaneous), but it may be a part of the autonomic system.

The terminal nerve is apparently sensory, but it is unrelated to olfaction. Plate (1922) suggested that this nerve is a special part of a nerve which performs a special olfactory function in aquatic animals, whereas it acts as a Jacobson's organ nerve in the terrestrial forms. On the other hand, Kent (1978), and Romer and Parson (1985) suggested that, the function of the terminal nerve is not clear.

In the current study the terminal ganglion is formed extracranially within the olfactory capsule. This agrees with Omar (2013) on *Coluber rogersi*. On the contrary, in other studies that described by Hegazy (1976), Mostafa (1990) and Abdel-Kader (2005) in Ophidia as they recorded that the terminal nerve carries the terminal ganglion intracranially near its termination in the forebrain.

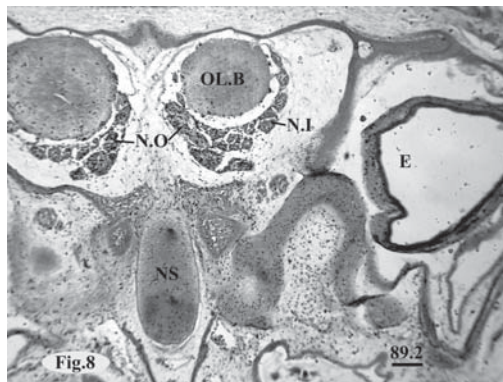


Fig. 8. Showing the passage of the nervi terminalis and vomeronasal ventromedial to the olfactory bulb (O.L.B).

It was found that the nervus terminalis of fishes, amphibians, reptiles and mammals bear during its course one or two ganglia terminale (Dakrory, 1994). However, this ganglion is absent in *Mustelus* among fishes (McKibben, 1914), rarely found in urodele amphibians and is not represented in some mammals (Grüneberg, 1973).

The connection of the vomeronasal nerve fibres with the vomeronasal organ from one hand and with the accessory olfactory bulb on the other hand met with in the present study, is the case found in the snakes described by Hegazy (1976), Mostafa (1990), Abdel-Kader et al., (2000),

El-Ghareeb et al. (2004) and Dakrory and Mahgoub (2009) and also in the lizards studied by Dakrory (2005), El-Ghareeb (1997) and Shamakh (2009). According to Bellairs (1950), this condition seems to be a common character in Rhynchocephalia and squamates.

The vomeronasal nerve, Jacobson's organ and the accessory olfactory bulb are not represented in the chelonians and crocodylians among reptiles (Jollie, 1968), Romer and Parson (1985) and in all birds (Soliman et al., 1986). Among mammals, these structures are lacking in many bats, in various aquatic forms as in whales, some carnivores, and in man and other higher primates as maquette (Crosby and Humphery, 1939; Mann, 1961; Jollie, 1968; Bhatnagar and Kallen, 1974). There is a concept which has been accepted among morphologists that the accessory olfactory bulb (vomeronasal formation) is apparently restricted to animals having a vomeronasal organ.

## Conclusion

Two nerves emerge from the vomeronasal organ which is part of the olfactory apparatus. They are the terminal and vomeronasal nerves that arise in combination. The terminal nerve has scattered ganglionic cells which represent the ganglion terminale.

## References

- Abdel-Kader, I. Y. 2006. The cranial nerves of the cat snake *Telescopus dhara* (Colubridae, Ophidia): I. The eye muscle nerves and the ciliary ganglion. *J. Egypt. Ger. Soc. Zool.*, **50** (B), 1–16.
- Abdel-Kader, I. Y., Soliman, M. A., Hegazy, R. M. 2000. Innervation of the nasal region of the Egyptian cobra *Naja haja haja*. *J. Egypt. Ger. Soc. Zool.*, **33**, 57–76.
- Abdel-Kader, T. G. 2005. *Anatomical studies of the blind snake Leptotyphlops cairi* (Family: Leptotyphlopidae). PhD thesis, Helwan Univ., Egypt.
- Abdel-Kader, T. G., Shamakh, A. A., Dakrory, A. I. 2007. The cranial nerves of *Mabuya quinquetaeniata*. I. The eye muscle nerves and the ciliary ganglion. *Egypt. J. Zool.*, **49**, 193–209.
- Alfitouri, Z. R. 2010. Innervation of the olfactory apparatus of the gecko *Tropicolotes tripolitanus* (Squamata–Lacertilia–Geckonidae). *Egypt. J. Zool.*, **55**, 85–100.
- Bellairs, A. d'A. 1950. Observation on the cranial anatomy of *Anniella*, and a comparison with that of other burrowing lizards. *Proc. Zool. Soc. Lond.*, **119** (4), 887–904.
- Bernhard, G. 1971. *Crzaimek's Animal Life Encyclopedia*. McGraw-Hill Publishing co., New York, 1–374.
- Bhatnagar, K. P., Kallen, F. C. 1974. Morphology of the nasal cavities and associated structures in *Artibeus jamaicensis* and *Myotis lucifugus*. *Amer. J. Anat.*, **139**, 167–190.
- Crosby, E. C., Humphrey, T. 1939. A comparison of the olfactory and the accessory olfactory bulbs in certain representative vertebrates. *Michigan Acad. Sci., Arts & Let.*, **24** (2), 95–104.
- Dakrory, A. I. 1994. *Anatomical studies on the cranial nerves of the Amphisbaenian (Diplometoponzarudnyi)*. MSc thesis, Cairo Univ., Egypt.
- Dakrory, A. I. 2005. The innervation of the olfactory apparatus of the bird snake *Leptotyphlops cairi* (Dumeril and Bibron, 1844). *Egypt. J. Zool.*, **45**, 201–214.
- Dakrory, A. I., Mahgoub, A. F. 2009. Innervation of the olfactory apparatus of *Echis carinatus* (Ophidia: Viperidae). *Egypt. J. Zool.*, **53**, 535–551.
- Dakrory, A. I., Omar, A. R. 2014. Comparative Anatomical Study on The Ciliary Ganglion of Snakes (Reptilia–Squamata–Ophidia). *Intern. J. Adv. Res.*, **9** (2), 518–529.
- Dakrory, A. I., Issa, A. Z., Ali, R. S. 2011. Nervi Terminalis, Vomeronasalis and Olfactorius of *Uromastix aegyptius* (Squamata–Lacertilia–Agamidae). *Life Science J.*, **8** (4), 900–907.
- De Beer, G. R. 1924. Contributions to the study of the development of the head in *Heterodonotus*. *Q. J. Micr. Sci.*, **68**, 39–65.
- El-Ghareeb, A. A. 1997. *Anatomical studies on the cranial nerves of the lizard Acanthodactylus boskianus* (Daud). PhD thesis, Cairo Univ., Egypt.
- El-Ghareeb, A. A., Abdel-Kader, I. Y., Mahgoub, A. F. 2004. The cranial nerves of the snake *Natrix tessellata* (Ophidia, Colubridae). The nervi terminalis, olfactorius, opticus and octavus. *Egypt. J. Zool.*, **43**, 309–332.
- El-Toubi, M. R., Kamal, A. M., Zaher, M. M. 1973. The development of the chondrocranium of the snake, *Malpolon monospessulana*. II. The fully formed stage. *Acta Anat.*, **85**, 593–619.
- Grüneberg, H. 1973. A ganglion probably belonging to the N. Terminalis System in the nasal mucosa of mouse. *Z. Anat. Entwickl. Gesch.*, **140**, 39–52.
- Hegazy, M. A. 1976. *Comparative anatomical studies on the cranial nerves of Ophidia*. Ph.D. Thesis, Faculty of science, Cairo Univ., Egypt.
- Jollie, M. T. 1968. The head skeleton of a new-born *Manis javanica* with comments on the ontogeny and phylogeny of the mammal head skeleton. *Acta Zool.*, **49**, 227–305.

- Kent, G. C. 1978. *Comparative anatomy of the vertebrates*. C. V. Mosby Co., Saint Louis, 1–465.
- Madboly, N. M. 2011. *Anatomical studies on the cranial nerves of Mabuya quinquetaeniata*. B. Sc. Fac. Sci. thesis, Helwan Univ., Egypt.
- Mann, G. 1961. Bulbusolfactorius accessories in Chiroptera. *J. Comp. Neurol.*, **116**, 135–141.
- McKibben, P. S. 1914. Ganglion cells of the nervus terminalis in the dog-fish (*Musteluscanis*). *J. Comp. Neurol.*, **24**, 159–175.
- Mostafa, R. H. 1990. The nervi terminalis and vomeronasalis and olfactorius in Ophidia. *Egypt J. Anat.*, **13** (2), 259–269.
- Mostafa, R. H. 1991. The ethmoidal ganglion and its relations in Ophidia (Squamata: Reptilia). *Proc. Egypt. Acad. Sci.*, **41**, 107–117.
- Northcutt, R. G., Puzdrowski, R. L. 1988. Projections of the olfactory bulb and nervus terminalis in the silver lamprey. *Brain Behav. Evol.*, **32**, 96–107.
- Omar, A. R. 2013. *Anatomical Studies on the Cranial Nerves of the Snake Coluber rogersi*. PhD thesis, Cairo Univ., Egypt, 1–171.
- Pinkus, E. 1894. Über einen noch nicht beschriebenen Hirnnerven d. *Protopterus annectens*. *Anat. Anz.*, **9**, 562–566.
- Plate, L. 1922. *Allgemeine Zoologie und Abstammungslehre*. TL. I. Jena, 1–640.
- Romer, A. S., Parson, T. S. 1985. *The Vertebrate Body, 6th edit*. W. B. Saunders Co., Philadelphia and London, 1–710.
- Salah EL-Din, E. Y., Dakrory, A. I. 2015. Embryonic Developmental Study on Vomeronasal Organ of Montpellier Snake (*Malpolon monspessulana*). *World Journal of Zoology*, **10** (2), 70–77.
- Shamakh, A. A. 2009. Innervation of the olfactory apparatus of *Laudakiastellio* (Reptilia–Squamata–Agamidae). *Egypt. J. Zool.*, **52**, 453–469.
- Soliman, M. A., Hegazy, M. A., Mokhtar, F. M., Mostafa, R. H. 1986. The cranial nerves of Birds. I. the main special sensory nerves, nervusolfactorius, nervusopticus and nervusoctavus. *Proc. Zool. Soc. A.R.E.*, **10**, 211–232.
- Von Bartheld, C. S., Lindorfer, H. W., Meyer, D. L. 1987. The nervus terminalis also exists in cyclostomes and birds. *Cell Tissue Res.*, **244**, 181–186.
- Watanabe, T., Yasuda, M. 1968. Comparative and Topographical anatomy of the fowl: II. Peripheral course of the olfactory nerve in the fowl. *Jap. J. Vetr. Sci.*, **30**, 275–279.

Received 21 July 2015

Accepted 23 February